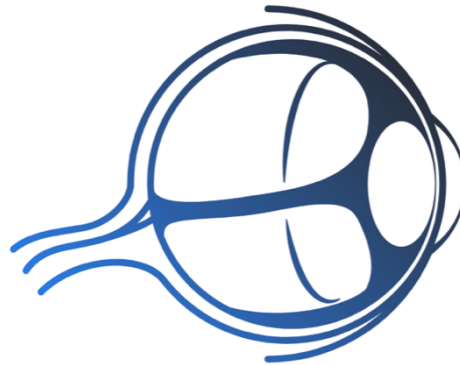



EALÉ'S DISEASE



Eye Learn
All about the Eye

Dr. Krati Gupta
Dr. Saurabh Deshmukh

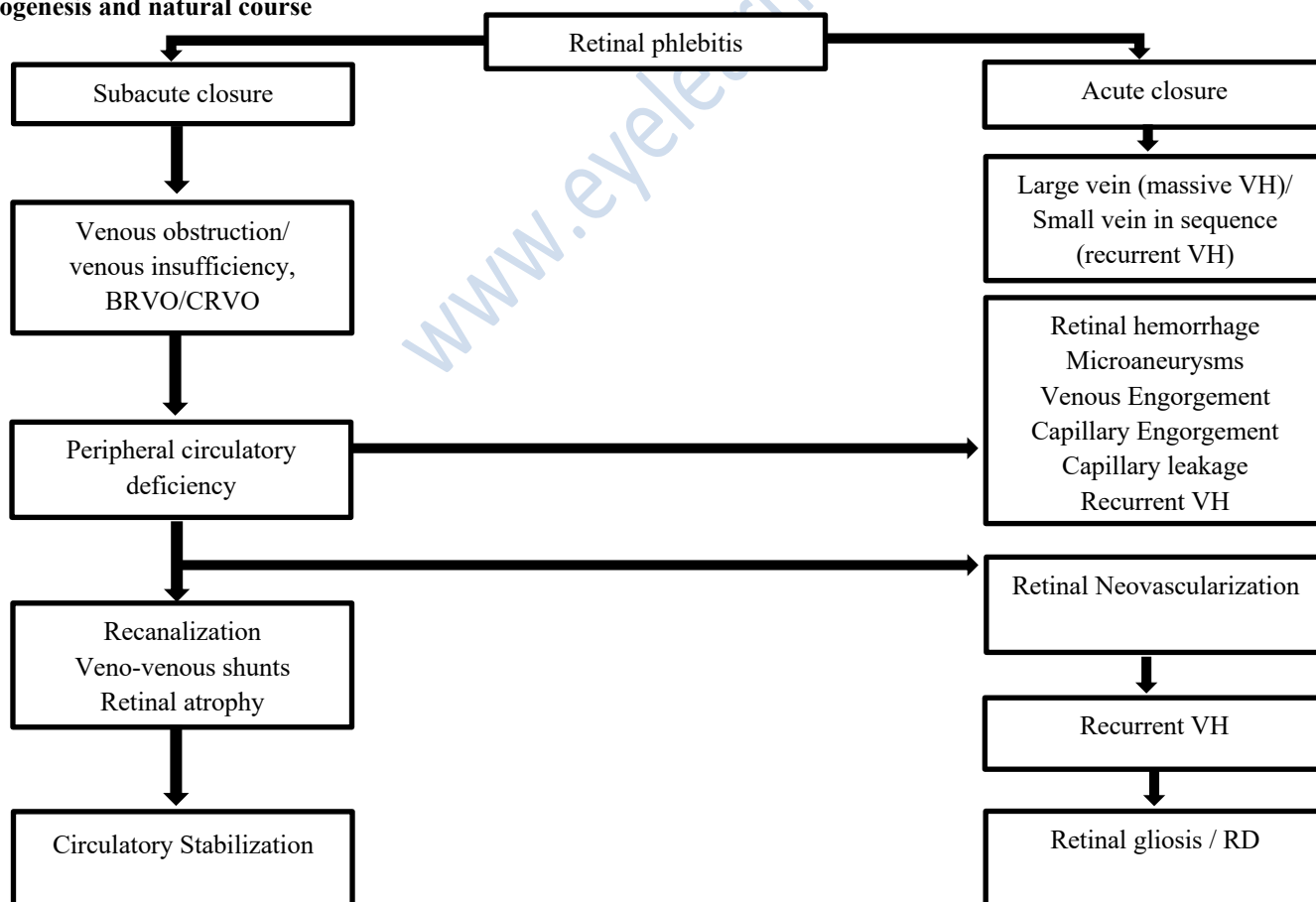
www.eyellearn.in



Stage		Features	Management
Stage 1 stage of inflammation	Stage 1a	Periphlebitis of small caliber vessels with superficial retinal hemorrhages	Medical therapy
	Stage 1b	Periphlebitis of large caliber vessels with superficial retinal hemorrhages.	
Stage 2, stage of ischemia and neovascularization	Stage 2a	Peripheral capillary nonperfusion.	Observation/ Laser photocoagulation
	Stage 2b	Neovascularization elsewhere /Neovascularization of the disc.	
Stage 3 stage of proliferation	Stage 3a	Fibrovascular proliferation.	Laser / pars plana vitrectomy and laser.
	Stage 3b	Vitreous hemorrhage.	
Stage 4 stage of complications	Stage 4a	Traction / combined rhegmatogenous detachment.	Sophisticated surgical Management strategies
	Stage 4b	Rubeosis iridis, neovascular glaucoma, Complicated cataract, and optic atrophy.	

- A. Eale's disease
- B. Central Eale's disease

Pathogenesis and natural course



Differential diagnosis



Eye Learn
All about the Eye

Systemic	Ocular
<ol style="list-style-type: none">1. Behçet's disease2. SLE3. Wegner's granulomatosis4. Sarcoidosis5. Syphilis6. Tuberculosis7. Toxocariasis8. Toxoplasmosis9. Lymes borreliosis10. Diabetes mellitus11. Sickle cell disease12. Leukemia13. Multiple sclerosis	<ol style="list-style-type: none">a. BRVOb. CRVOc. Coat's diseased. Bird shot choroidopathye. Pars planitisf. IRVANg. VH in retinal tears (young myopes)

www.eyelearn.in