PSEUDOPHAKIC BULLOUS KERATOPATHY

Eye Learn

All about the Eye

Dr. Krati Gupta

Dr. Saurabh Deshmukh

www.eyelearn.in

PSEUDOPHAKIC BULLOUS KERATOPATHY

1. What is pseudophakic bullous keratopathy? Etiopathogenesis, clinical features and management of pseudophakic bullous keratopathy.(1+2+3+4) **J2015**
2. Write down the methods of prevention and management of pseudophakic bullous keratopathy. **D2009**
3. Discuss etiopathology of Pseudophakic Bullous Keratopathy. **(2000)**
4. Causes, clinical presentation and treatment modalities for pseudophakic bullous keratopathy. (3+2+5) **J2017**
5. 52 Y F underwent phacoemulsification 3 week back & has persistent corneal edema. DD. Approach in evaluating and investigating the patient. Management. Precautions while planning surgery of the other eye (2+4+3+1)

Definition

- PBK refers to the development of irreversible corneal edema following cataract surgery which initially develops in stroma progressing towards intercellular epithelial region with characteristic formation of bullae.
- Pseudophakic bullous keratopathy is characterized by corneal stromal edema with epithelial and subepithelial bullae due to cell loss and endothelial decompensation through trauma during cataract surgery.
- Though with newer surgical techniques and IOL designs, incidence of this complication has decreased dramatically, it still represents an important cause of visual disability following routine and complicated cataract surgery

Pathophysiology

- Corneal transparency depends on ability of cornea to remain in dehydrated state.
- Corneal epithelium and endothelium are both semipermeable membranes that create a barrier to the flow of water and other electrolytes.
- The major factor which prevents corneal hydration is **Na+K+ATPase pump** which lies within lateral cell membrane in endothelial layer of cornea.
- Endothelium is incapable of mitotic activity. At birth endothelial cell count is approximately 7500 cells /mm^2. In older adults it is approx. 2500-2700 cells / mm^2. Normal rate of endothelial cell loss after age of 20 is approx. 0.5 %per year.
- Surgical trauma, inflammation and corneal dystrophies (Fuch's endothelial dystrophies, posterior polymorphous dystrophies) can accelerate this normal aging loss.
- The final common pathway in development of PBK is damage to corneal endothelium when cell density reaches to critically low level of about 300-500 cells / mm^2.
- It leads to rearrangement of remaining cells to cover posterior corneal surface in the form of polymegathism (greater than normal variation of corneal endothelial cell size resulting in irregular large and small cells) and pleomorphism (variation in cell shape; increased proportion of non-hexagonal cells).
- Descemet's membrane is produced in excess amount.
- Endothelial pump fails and stromal edema develops.
- Edema may fluctuate in response to changing I.O.P. (Imbibition pressure = I.O.P.- Swelling pressure).
- Later on epithelial edema ensues because of anterior movement of aqueous and fluid in stroma leading to formation of blisters and bullae.

- Condition typically worsens during night because of lack of evaporation and lack of hypertonic environment.

Histopathology of PBK

- Prime feature is attenuation and loss of corneal endothelial cells with associated epithelial bullae and stromal edema.
- There is thickening of the posterior collagenous layer of Descemet's membrane and decrease in stromal keratocytes
- The lack at adhesive proteins in epithelial basement membrane (fibronectin, laminin and collagen type IV) and accumulation of antiadhesive proteins, such as tenacin C and thrombospondin -1, leads to loss of contact of epithelial cells with each other and with underlying subepithelial tissue, resulting in subepithelial bullae and fibrosis.

Incidence: Current incidence is about 0.1% FDA report on intraocular lens (1978-1982)

Table 1: Association of PBK with of intraocular lens

Incidence of PBK	Type of lens
0.06%	PC IOL
1.2 %	AC IOL
1.5 %	Iris fixated lens

Table 2: Endothelial cell loss in cataract surgery

ECCE	SICS	PE
4.72 %	4.21%	5.41%

Clinical features

Patients present with decreased vision, tearing, and pain caused by ruptured epithelial bullae.

Symptoms	
Poor visual acuity	Due to inability of stroma to maintain corneal transparency. Epithelial oedema can be responsible for great changes in visual activity due to irregularity in corneal refractive surface. Mild stromal edema doesn't cause severe visual loss. However epithelial oedema can cause a significant drop in vision.
Pain / discomfort	Pain occurs due to exposure of corneal nerves to noxious environment
Pain, photophobia & epiphora	As the edema progresses, bullae are formed their rupture results in pain, photophobia & epiphora.
Signs- SLE	
Cornea	Folds in DM and obvious overall thickening of central and peripheral cornea. In more advanced cases, vesicles & bullae may be seen on corneal surface.
Corneal guttata	Seen in patients with predisposing conditions (like fuch's dystrophy & Posterior Polymorphous dystrophy). Guttata excrescences appear as "golden brown" confluent endothelial lesions & give posterior surface a "beaten metal appearance.

Etiology

Preoperative risk factors

Endothelial dystrophy	Incidence of preoperative endothelial dystrophy in PBK has been found in 67% of patients
Pseudoexfoliation syndrome	Increased incidence of PBK, due to higher rate of vitreous loss. Due to clinically & histopathologically distinct keratopathy (Irregular thickening of DM and focal accumulation of locally produced PXE material). A reduced preoperative endothelial cell count of 10.5 to 11.1% is seen in PXE
Endothelial cell density < 2000 cells/mm^2	Seen in history of corneal diseases, angle closure glaucoma, pseudoexfoliation syndrome and a history of trauma

Specular microscopy:

- Though there is no direct correlation between endothelial cell density and oedema, significant correlation has been found between variation in cell shape (Plesmorphism) and size (Polymegathism) and development of postoperative corneal oedema.
- Pleomorphic cells react adversely to intraocular surgery. Polymegathic cells may not fit together leaving gaps and compromising the endothelial structural barrier.

Intraoperative risk factors

Surgical trauma to endothelium ,Type of cataract surgery

- **IOL**-Lenses made of methacylate adhere instantaneously to endothelial surface when contact upon lens insertion occurs.
- **Cannulas**- Reusable cannulas with viscoelastic can result in toxic residues being introduced into the eye. Hence disposable annuals should be used.
- **I&A-**
  i. During **intraocular irrigation**, physiologic saline causes corneal swelling and endothelial damage.
  ii. Ringer's solution does so to a lesser degree.
  iii. Balanced salt solution enriched with bicarbonate, dextrose and glutathione (BSS plus) has been shown to protect the endothelium better than BSS alone.
  iv. Intraocular irrigation must be just adequate enough. Excess may cause endothelial injury.
- **Viscoelastics-**
  i. It has been found that **HPMC** is not as protective as sodium hyaluronate during phacoemulsification.
  ii. Protective benefit of sodium hyaluronate is improved when used in combination with chondroitin sulphate.
- **Toxic substances used to disinfect instruments** may inadvertently be introduced into the eye. Water, not saline, should be used to rinse the instruments.
- **Drugs-**
  i. For topical and intracameral anesthesia only 0.5 ml of 1% preservative free lidocaine should be used.
  ii. Other preparations may cause corneal toxicity.
  iii. Intraocular epinephrine, benzalkonium chloride preserved viscoelastic, vancomycin (> 1 mg / ml) and inadvertent exposure of endothelium to 5% povidone-iodine can cause endothelial toxicity.

- **Descemet's detachment-** is more common with clear corneal incisions which may lead to postoperative corneal edema.

Postoperative causes

- Routine uncomplicated phacoemulsification results in 9% endothelial cell loss at 1 year postoperatively.
- In one series, it has been found to be 11.9%
- Regardless of type of surgery and type of IOL implanted, continuing endothelia cell loss more than usual 1% per year occurs in patients who have undergone cataract extraction.

Type of lens implanted

- ACIOLs contribute to endothelial damage by "Intermittent touch" between IOL & corneal.
- IOL haptics & footplates can cause chronic irritation with low grade inflammation
- IOLs are also known to disrupt the normal flow of aqueous in anterior chamber which is the nutrient flow to endothelial cells.
- Iris supported lenses may cause greater endothelial loss as they can have contact with endothelium during ocular saccades.
- Closed loop ACIOL have been responsible for large amount of corneal pathology.

Evaluation and Imaging Studies

Specular microscopy

- This is photographic method of assessment of endothelium in vivo.
- Light is projected onto cornea and reflected images from optical interface (endothelium and aqueous) can be visualized.
- High magnifications photographs allows quantification of cell density.
- Corneal cell densities < 1000 cells / mm^2 are at moderate to high risk of developing corneal edema following intraocular surgery.
- Digital analysis of photographs can be used to assess parameters such as coefficient of variation (for polymegathism) and percentage of hexagonal cells present (for pleomorphism).
- Endothelial cells that show great variability in size and shape are considered to be under physiologic stress and are abnormal.
- Specular photomicrographs can be used to assess corneal diseases:
    - Fuch's dystrophy shows guttate excrescences.
    - Posterior polymorphous dystrophy shows patchy areas of normal endothelium adjacent to abnormal endothelium with vesicles and plaques.

Ultrasound pachymetry and optical pachymetry

- Both are used to measure corneal thickness.
- (N) Central corneal thickness is 550 um centrally increasing up to 770um peripherally.
- Corneal thickness above 0.6 mm (600 um) is suspect for corneal edema.
- Serial measurements are helpful to note progression; and also to assess effectiveness of therapeutic regimens.
- Ultrasonic pachymetry is more reproducible and requires less skill than optical.

- Optical pachymetry is especially useful in measuring the depth of corneal pathology, when full thickness of corneal stroma is not involved and for therapeutic reasons to estimate the depth of this pathology.
- It is preoperative investigation for excimer laser phototherapeutic keratectomy.
-

Management

Medical	1. Topical hyperosmotic agent- 2% and 5% sodium chloride solution and ointment. 2. Pressure lowering agents 3. Topical steroids 4. Hydrophilic contact lenses 5. Systemic L cysteine
Surgical	1. Conjunctival flap 2. Amniotic membrane transplantation 3. Cautenisation of Bowman's membrane 4. Anterior stromal puncture in bullous keratopathy 5. Annular keratotomy 6. Phototherapeutic keratectomy for bullous keratopathy 7. Corneal transplantation 8. DLEK (Deep lamellar endothelial Keratoplasty) 9. Flap endokeratoplasty 10. CXL

Medical Care

1. Topical hyperosmotic agent- 2% and 5% sodium chloride solution and ointment.

- **Mechanism**:
  - These agents create hypertonic tear film, drawing water out of cornea.
  - Because evaporation of tear film is minimal at night with eyes closed, corneal edema tends to be worse in morning.
  - Hence 5% sodium chloride ointment should be applied at nigh to conjunctival cul-de-sac.
- **Dose-**
  - Regimen includes application NaCl hypertonicity solution, 2-5% drop hourly in affected eye until noon.
  - As the day progresses, evaporation of tear film begins to create relative hypertonicity of tears drawing fluid out of cornea.
  - This accounts for typical history of improving vision towards end of the day.

2. Pressure lowering agents

- Lowering of IOP can decrease corneal edema & thickness in postoperative setting, even if IOP is normal or only mildly elevated.
- β-blockers & -agonists are first line agents for this purpose.
- Prostaglandins analogs & miotics should be avoided because both drugs may adversely affect intraocular inflammation.
- Utility of topical CA (-) is under question because they may cause endothelial toxicity in compromised corneas.

3. Topical steroids

- These should be used in cases of uveitis provided infectious keratitis & epithelial defects are absent.

4. Hydrophilic contact lenses

- These on extended wear basis, can be used to decrease pain associated with epithelial bullae but do not reduce the amount of edema.
- These can improve visual activity to the extent that they mask surface irregularity.
- These contact lenses can be used in association with 5% hypertonic saline (as cornea) and thus they can improve visual acuity by decreasing epithelial & stromal edema.
- Pain associated with PBK can be due to rupture of bullae with exposure of corneal nerves endings or swelling of epithelium leading to stretching of nerve endings.
- These lenses alleviate pain as long as the lens remains in place.
- Acts as effective precorneal protective layer.
- Shields abnormal epithelium from environment and prevents bullae from bursting.
- The lens doesn't prevent formation of bullae but perhaps when new bullae do occur, the corneal nerves' endings are not exposed to drying & other noxious stimuli, when the lens cover them.
- Fitting of lens is an important consideration.
- Lenses with excessive movement can irritate epithelium & be uncomfortable.
- Lenses that are too tight can act as suction cap and result in inflammation and even anterior uveitis (Tight lens syndrome).

5. Systemic L-cysteine

- According to a study conducted in 2015, systemic L-cysteine facilitated corneal edema remission in cataract surgery postoperative period, thus advocating its concurrent use in patients developing bullous keratopathy.
- An increased expression of several pro-inflammatory mediators at the protein level in the corneal epithelium was demonstrated in patients with pseudophakic corneal edema.
- These cytokines and MMP, which are a family of extracellular proteinases that degrade the extracellular matrix proteins, participate in the pathologic processes in the pseudophakic corneal edema and specifically contribute to the continuous degradation of Bowman's layer and recurrent erosions of the corneal epithelium.
- The MMPs have a pivotal role in a number of pathologic processes, including angiogenesis and wound healing, where matrix degradation takes place.
- MMP are activated by the "cysteine switch".
- All modes of activation lead to a dissociation of Cys73 from the zinc atom with concomitant exposure of the active site.
- Based on the presumption that high L-cysteine levels may act as regulatory substrate for MMPs, more studies should be conducted in order to establish the adjuvant role of systemic L-cysteine in pseudophakic bullous keratopathies.

Surgical Care

1. Conjunctival flap

- In 1958, Gundersen introduced the technique of using only flap of thin conjunctiva without use of tenon's capsule to cover the cornea.
- The exclusion of tenon's capsule increases flap longevity.
- It undermines the superior bulbar conjunctiva & moves in & down to cover the cornea with intact "bridges" nasally and temporally.
- The flap is thought to increase the local blood supply, promote healing and replace damaged or defective corneal epithelium.
- Unacceptable cosmetic outcome.

2. Amniotic membrane transplantation

- **Rationale**- AM to control pain in patients with BK.
- They attributed their results to various protease inhibitors located in the stromal matrix of the AM, which are important for promoting epithelial healing and reducing stromal ulceration and inflammation.
- AM facilitates re-epithelialization by providing a suitable substrate and a normal basement membrane, by promoting epithelial cell migration and adhesion.
- AM is also believed to produce several growth factors that support epithelial cells. When the amniotic membrane is applied to the cornea, keratocyte derived fibroblasts and myofibroblasts are known to migrate from the corneal stroma into the amniotic stroma.
- This contributes to the subepithelial fibrosis and also anchors the amnion epithelial sheet to the corneal surface
- Amniotic membrane transplant is effective in controlling pain in patients with pseudophakic bullous keratopathy and does not induce neovascularization, but is not the first treatment option because of the cost and needed time.

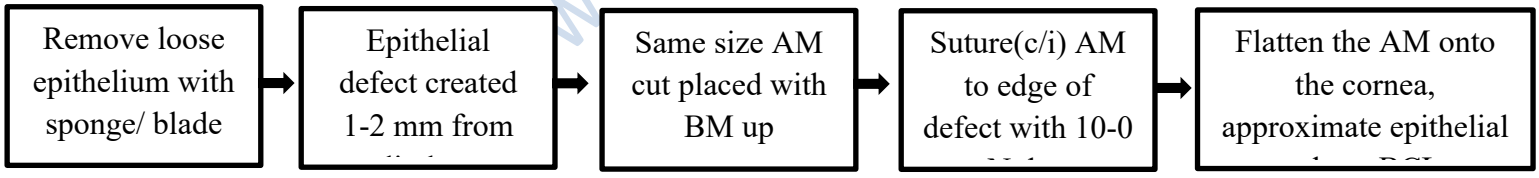

- The side of BM could be distinguished from stromal side by touch with sponge. The former was not sticky, while the later was & could be caught by the sponge.

- Advantages of AMT

Good pain relief	Easier to perform
Restores corneal epithelial integrity	Reinforces adhesion of basal epithelial cells
Avoid potential complications of conjunctival flap such as ptosis, it gives better cosmetic appearance	Prevents epithelial apoptosis, enhances epithelial migration, differentiation
Cornea doesn't manifest surgically induced LSCD as caused by conjunctival flap thus PK can be done later on	Provides new and non-antigenic human basement membrane for renewed expansion of epithelial cells.
Stromal matrix inhibits TGF-β, hence causing less scars postoperatively	Prolongs life span of corneal and conjunctival progenitor cells

3. Cautenisation of Bowman's membrane

- It can be performed for pain relief.
- This procedure is thought to produce dense fibrous barrier between corneal stroma and epithelium so that fluid cannot permeate into epithelial cells and produce bullous changes.

4. Anterior stromal puncture in bullous keratopathy

- **Rationale:** Immunohistochemical studies have demonstrated an increased expression of extracellular matrix proteins important for the adhesion of basal epithelial cells such as fibronectin, laminin, and type IV collagen at stromal puncture sites.
- The secretion of these basement membrane components would increase the epithelial adhesion in the underlying stroma, which is associated with subepithelial fibrosis, thus creating a barrier to liquid penetration into the subepithelial space and decreased subepithelial bubble formation
- Anterior stromal puncture is an effective, simple and low cost alternative for treating patients with symptomatic bullous keratopathy.

5. Annular keratotomy

- It is used to treat pain associated with bullous keratopathy in eyes with poor visual potential.
- A partial thickness corneal incision is made with a trephine and relieves pain by severing branches of corneal ciliary nerves to decrease corneal sensation.
- Diamond burr polishing of basement membrane
- Following epithelial debridement, 4.5 mm to 5 mm diamond burr can be used gently to polish basement membrane throughout area of epithelial debridement.

6. Phototherapeutic keratectomy for bullous keratopathy

- **Rationale**-PTK can improve pain by reducing corneal thickness and this would help the remaining endothelial cells maintain corneal hydration.
- Several studies reported PTK to be elective in the management of patients with bullous keratopathy from a variety of etiologies; they reported that the bullae resolve and pain is abolished in a large proportion of patients treated with a superficial ablation.
- The main sensory nerve plexus in the cornea, which is derived from the nasociliary branch of the ophthalmic division of the trigeminal nerve, is located in the stroma, in the immediately subepithelial region, with a lower density plexus deeper in the stroma. Pre-terminal neural plexus of cornea is located just deep to Bowman's membrane.
- The rationale for this treatment is the ablation of these nerve plexuses thereby reducing corneal sensation and, in addition, corneal scarring induces an increase of extracellular proteins such as laminin, fibronectin, type IV collagen and hemidesmosomes which promote a greater adhesion between the epithelium and stroma.
- Nidek EC 5000 excimer laser used for performing PTK (3 types) for PBK
    - Superficial PTK-8 to 25 µm ablation
    - Intermediate PTK -50 to 100 µm ablation
    - Deep PTK -25% of stromal thickness ablation
- Deep PTK appears to be more successful in comparison with superficial PTK because of the increased scarring associated may also result in an increased stability of the epithelium and a deep ablation has a superior effect on decreasing pain by the ablation of the neural plexus in the cornea .

- Moderately deep ablation would have superior effect on decreasing the pain; by ablation of neural plexus. It will lead to decreased swelling of corneal stroma by decreasing the quantity of mucopolysaccharides and hence decreasing osmotic load.

Automated lamellar keratectomy

- The same reasoning as in PTK is used also for automated lamellar keratectomy but, in this case, a traditional microkeratome is used for the removal of the corneal tissue.
- It is a fast procedure, which can be an important factor for some elderly patients who present difficulties in undergoing longer surgeries while remaining in dorsal decubitus

7. Corneal transplantation

Penetrating keratoplasty for PBK:

- Corneal transplantation is still the gold standard treatment for bullous keratopathy patients, as it provides symptomatic relief and visual rehabilitation.
- Some limitations such as visual acuity recovery occur because of the high astigmatism and, although the cornea is the most commonly transplanted tissue in the body and corneal grafts high success rate, there is also the risk of rejection .Commonest cause of graft failure was "graft rejection"(17.2%).
- Failure in PK for PBK d/t IOL
  - 34% ACIOL
  - 29% Iris supported lens
  - 6% PCIOL
- Explantation of all closed loop AC IOLs and iris claw IOLS and AC reconstruction during PK with IOL exchanged should be done using PCIOL or open loop Kelman type ACIOL. To avoid delay in corneal surgery once PBK is diagnosed
- Anterior segment reconstruction during PK →Better outcome, Anterior vitrectomy, + Gonioplasty, +Iridoplasty, Vitrectomy

Advantage of Anterior Vitrectomy	**Advantage of gonioplasty & Irioplasty**
• ↓ CME • Prevents decentration of IOL by vitreous strands	• To restore pupil to normal round configuration • Prevents development of glaucoma and allograft rejection related to formation of anterior synechiae due to centripetal tension exerted on iris. • Give additional support to AC lens. • Improves optical function of iris.

- CME is important cause for poor visual recovery in such patients.
- Despite risk of infection, secondary glaucoma and graft rejection, penetrating keratoplasty still remains treatment to get maximum improvement in visual acuity.

Options for IOL exchange are	**Flexible ACIOL should be reserved for**	**Sutured intraocular lenses should be reserved for**
• Modern flexible loop ACIOL. • PCIOL in ciliary sulcus. • Iris fixation of PCIOL. • Suturing of PCIOL in sulcus	• Eyes with minimal anterior segment pathology. • Less than 900 angle synechiae. • Well controlled I.O.P.	• Extensive anterior segment pathology. • Lack of iris support for ACIOL. • Patients with glaucoma.

8. DLEK (Deep lamellar endothelial Keratoplasty)

- In patients with normal stroma and superficial cornea, where only endothelium is damaged; this procedure is a very good treatment modality, with following distinct advantages:
- This preserves healthy portions of patients' native cornea.
- It avoids additional risks and postoperative complications.
- Additional benefit is that postoperative astigmatism is very minimal.
- Descemet's stripping (automated) EK (DSEK or DSAEK),
- Descemet's membrane EK, and Descemet's membrane automated EK

9. Flap endokeratoplasty

- "Flap endokeratoplasty versus penetrating keratoplasty for PBK: 5 yrs. follow up results".
- 5 yrs follow up shows all clear grafts no significant difference between BCVA, endothelial cell count or mean postoperative refraction.
- Visual recovery and postoperative astigmatism were better in patients who have undergone Flap EKP.
- Preliminary results show that flap EKP could be a successful alterative to penetrating keratoplasty for treatment of PBK.
- This might be the future as far as treatment of PBK is concerned.

10. Corneal collagen cross linking (CXL)

- CXLwith Riboflavin and UVA radiations is a photochemical process that was introduced by Seiler and Spoerl at the University of Dresden for the treatment of corneal ectatic disorders such as keratoconus and post LASIK ectasias.
- Corneal CXL is considered a new tool in the struggle for the temporary reduction in corneal edema in patients with bullous keratopathy.
- It has been found to improve corneal transparency, corneal thickness, and ocular pain after surgery
- The proposed mechanism of action is that riboflavin absorbs UVA light, which results in the production of free oxygen radicals.
- These highly reactive oxygen radicals then induce the crosslinking of corneal stromal collagen and strengthen the cornea.
- Different studies showed that corneal CXL significantly improves corneal transparency, corneal thickness, and ocular pain one month postoperatively.
- This symptomatic relief probably resulted from CXL-induced stromal compaction and reduced bullae formation.
- However, it did not seem to have a long-lasting effect in decreasing pain and maintaining corneal transparency.