
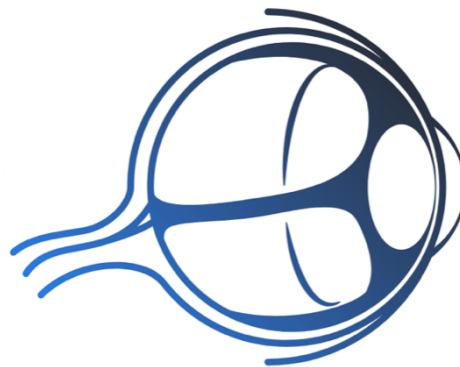


# SURGICAL WOUND CLOSURES FOLLOWING PTERYGIUM EXCISION



**Eye Learn**

All about the Eye

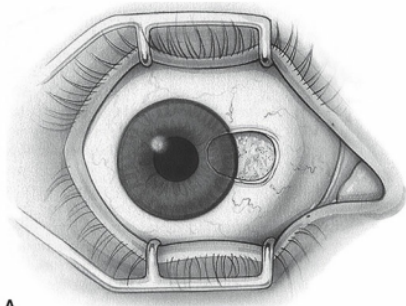
Dr. Krati Gupta

Dr. Saurabh Deshmukh

[www.eyelearn.in](http://www.eyelearn.in)

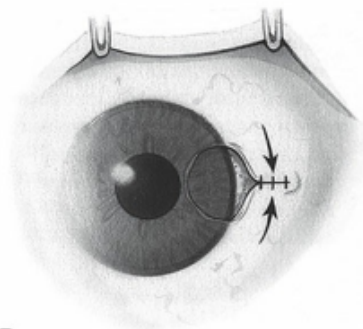


## SURGICAL WOUND CLOSURES FOLLOWING PTERYGIUM EXCISION



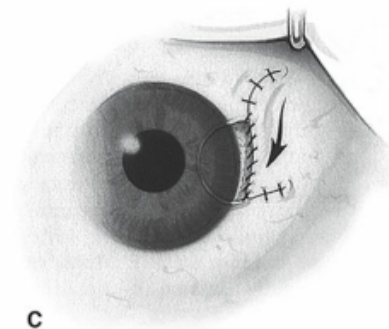
A

A] Bare sclera



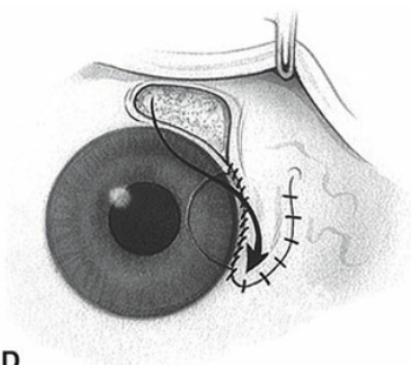
B

B] Simple closure with fine, absorbable sutures.



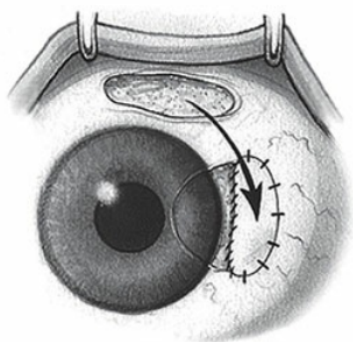
C

C] Sliding flap that is closed with interrupted and/or continuous suture.



D

D] Rotational flap from the superior bulbar conjunctiva.



E

E] Conjunctival autograft that is secured with interrupted and/or continuous suture

[www.eyelearn.in](http://www.eyelearn.in)